



Provided by the author(s) and University of Galway in accordance with publisher policies. Please cite the published version when available.


Title	A standardized aspiration-first approach for thrombectomy to increase speed and improve recanalization rates
Author(s)	O'Neill, D.; Griffin, E.; Doyle, Karen M.; Power, S.; Brennan, P.; Sheehan, M.; O'Hare, A.; Looby, S.; da Silva Santos, A. M.; Rossi, Rosanna; Thornton, J.
Publication Date	2019-08-14
Publication Information	Neill, D., Griffin, E., Doyle, K. M., Power, S., Brennan, P., Sheehan, M., Hare, A., Looby, S., da Silva Santos, A. M., Rossi, R., Thornton, J. (2019). A Standardized Aspiration-First Approach for Thrombectomy to Increase Speed and Improve Recanalization Rates. <i>American Journal of Neuroradiology</i> , 40(8), 1335. doi: 10.3174/ajnr.A6117
Publisher	American Society of Neuroradiology
Link to publisher's version	https://doi.org/10.3174/ajnr.A6117
Item record	http://hdl.handle.net/10379/17636
DOI	http://dx.doi.org/10.3174/ajnr.A6117

Downloaded 2024-04-25T14:19:05Z

Some rights reserved. For more information, please see the item record link above.



A Standardized Aspiration-First Approach for Thrombectomy to Increase Speed and Improve Recanalization Rates

 D. O'Neill,  E. Griffin,  K.M. Doyle,  S. Power,  P. Brennan,  M. Sheehan,  A. O'Hare,  S. Looby,  A.M. da Silva Santos,  R. Rossi, and  J. Thornton

ABSTRACT

BACKGROUND AND PURPOSE: Direct aspiration is a recognized technique for revascularization in large-vessel ischemic strokes. There is ongoing debate regarding its efficacy compared with stent retrievers. Every delay in achieving revascularization and a decrease in reperfusion rates reduces the likelihood of patients achieving functional independence. We propose a standardized setup technique for aspiration-first for all anterior circulation thrombectomy procedures for increasing speed and recanalization rates.

MATERIALS AND METHODS: We analyzed 127 consecutive patients treated by a standardized approach to thrombectomy with an intention to perform aspiration-first compared with 127 consecutive patients treated with a stent retriever-first approach. Key time metrics evaluated included groin to first angiogram, first angiogram to reperfusion, groin to first reperfusion, and length of the procedure. The degree of successful recanalization (TICI 2b–3) and the number of passes were compared between the 2 groups.

RESULTS: In 127 patients who underwent the standardized technique, the median time from groin puncture to first reperfusion was 18 minutes compared with 26 minutes ($P < .001$). The duration of the procedure was shorter compared with the stent retriever group (26 minutes in the aspiration first group versus 47 minutes, $P < .001$) and required fewer passes (mean, 2.4 versus 3.1; $P < .05$). A higher proportion of patients had a TICI score of 2b–3 in the aspiration-first group compared with stent retriever group (96.1% versus 85.8%, $P < .005$).

CONCLUSIONS: Our study highlights the increasing speed and recanalization rates achieved with fewer passes in a standardized approach to thrombectomy with an intention to attempt aspiration-first. Any attempt to reduce revascularization time and increase successful recanalization should be used.

ABBREVIATIONS: ADAPT = A Direct Aspiration First Pass Technique; ENT = emboli to a new territory; IQR = interquartile range; RCT = randomized controlled trial

Every incremental delay in achieving vessel recanalization in patients with large-vessel ischemic stroke results in a reduced likelihood of achieving an independent functional outcome following thrombectomy.¹ Thrombectomy is the standard of care in acute ischemic stroke with large-vessel occlusion in selected patients presenting up to 24 hours after the onset of symptoms.² Most trials have primarily used second-generation stent retriever devices.³ However, aspiration techniques have also been described and demonstrated to be successful but appear to be less widespread in their use.^{4–6} The COMPASS Trial: A Direct Aspiration First Pass Technique (COMPASS) has shown noninferiority of direct aspiration compared with a primary stent retriever.⁷ The

likelihood of good clinical outcome depends on the speed and completeness of the recanalization achieved. We propose a technique that can be used as a standardized approach for all thrombectomy procedures, resulting in faster groin-to-recanalization times with an increased rate of successful recanalization and fewer passes than previously published.

MATERIALS AND METHODS

We maintain a prospective data base for ongoing audit and quality improvement with detailed analysis of all thrombectomy procedures in our institution in Beaumont Hospital. This is under the remit of ongoing service audit and is therefore excluded from the requirement for ethics approval. The ongoing audit of our service is registered with the Institutional Quality and Standards Department. Time metrics of each step in the process are gathered. We provide a 24-hour thrombectomy service for patients presenting to our comprehensive stroke center. We also accept referrals from 24 hospitals within the Republic of Ireland, using a drip and ship model and commonly also using a drip, ship, retrieve, and leave

Received February 25, 2019; accepted after revision May 31.

From the Interventional Neuroradiology Service (D.O., E.G., S.P., P.B., M.S., A.O., S.L., J.T.), Department of Radiology, Beaumont Hospital, Dublin, Ireland; Royal College of Surgeons (E.G., J.T.), Dublin, Ireland; and Department of Physiology (K.M.D., A.M.d.S.S., R.R.), School of Medicine, National University of Ireland, Galway, Ireland.

Please address correspondence to Emma Griffin, FAO, Department of Radiology, Beaumont Hospital, Dublin 9, Ireland; e-mail: emma.griffin.2@ucdconnect.ie

<http://dx.doi.org/10.3174/ajnr.A6117>

model with immediate repatriation to the hospital within a <1.5-hour transport distance. This model has previously been described in the literature.⁸ We perform endovascular thrombectomy in the anterior circulation with large-vessel occlusion within 24 hours of onset of symptoms, with ASPECTS of >5 and good (>50%) collateral circulation on triple-phase CTA.

Most patients come from outside institutions with stroke imaging work-up performed at the primary center. On arrival, they proceed directly to the Interventional Radiology suite or for a repeat CT in the same department if >2 hours have passed or if there has been clinical improvement or deterioration. For the cohort of patients in this study, CT perfusion was infrequently performed; however, the use of CTP is increasing in our department. Four interventional neuroradiologists perform the thrombectomy procedures. Three of our team have recently moved to a standardized approach to thrombectomy.

The standardized aspiration-first approach is as follows: An 8F short sheath is introduced to the common femoral artery with local anesthesia infiltrated in the overlying skin. Most patients are awake for the procedure. Conscious sedation and general anesthesia are infrequently used except in particularly agitated or unstable patients. A 6F Weinberg catheter (Balt Extrusion, Montmorency, France) inside an 8F MACH 1 Guide Catheter (Boston Scientific, Natick, Massachusetts) is advanced to the aortic arch with a 0.035-inch Glidewire (Terumo, Tokyo, Japan), and the relevant large vessel of the neck is catheterized. The 6–8F combination is then advanced in to the internal carotid artery with the 8F guide advanced over the 6F catheter for final tip placement in the proximal-to-mid-internal carotid artery. If there is a stenosis or occlusion of the ICA, an attempt is made to cross this first without angioplasty or stent placement. The wire and 6F Weinberg catheter are removed. Angiography confirms the site of vessel occlusion. Continuous heparinized saline flush is attached to the catheter through a pressure pump.

A 6F Sofia Plus 0.070-inch catheter (MicroVention, Tustin, California) is advanced through a rotating hemostatic Y-valve attached to a heparinized saline flush into the 8F guide catheter. A 20-mL syringe partially filled with saline is attached to the hub of the catheter, allowing back flow of blood in the absence of a wire within the catheter. Once the Sofia Plus catheter extends beyond the tip of the 8F guide catheter, the 20-mL syringe is switched, following aspiration of any blood, for a 10-mL contrast-filled syringe. Contrast is trickled forward as the Sofia Plus catheter advances. The Sofia Plus may be advanced through the distal internal carotid artery in this manner, with the operator being careful to avoid pushing against resistance. It is usually possible to push this catheter to the proximal end of the thrombus in the ICA or M1 segment. An inability to aspirate blood backwards through the Sofia Plus indicates engagement with the thrombus. A 50-mL Luer Lock lockable syringe is then attached to the catheter, and fixed suction is applied for approximately 30 seconds. It is usually necessary to withdraw the catheter a little into the proximal M1 or distal ICA, dislodging the thrombus before the thrombus is aspirated into the catheter and syringe and rapid back flow is obtained. Infrequently, back flow is not obtained, and the catheter has to be removed completely, usually due to thrombus at the tip of the catheter, and continuous aspiration is applied with the sy-

ringe, which is locked on suction. This appears more likely to happen with a “white clot.” Angiography will determine whether further aspiration is required or suitable.

Alternative steps are the following:

1) If the catheter will not advance distally in the internal carotid artery, a support wire may be used such as a 0.035-inch Glidewire, which is not advanced beyond the tip of the aspiration catheter.

2) If the aspiration catheter catches in the ophthalmic artery, which is a quite common occurrence, a 0.021- or 0.0027-inch microcatheter over a 0.014-inch wire may be advanced through the Sofia Plus into the distal ICA or MCA. This may be enough to allow the Sofia Plus to pass the ophthalmic artery. The inner microcatheter and wire may then be removed to allow the standard aspiration-first technique as described above.

3) If the Sofia catheter still does not go as far as the thrombus, the microcatheter-wire combination should be advanced beyond the thrombus as per standard stent retriever technique. Once beyond the thrombus, if the Sofia Plus has still not advanced, the stent retriever of choice may be deployed. Retrieval of the stent retriever to remove the clot usually allows advancement of the Sofia Plus catheter beyond the ophthalmic artery into the proximal end of the thrombus.⁹ The stent retriever may be retrieved entirely into the Sofia Plus catheter and removed. Ideally, the Sofia Plus catheter is maintained beyond the ophthalmic artery or in the M1 segment to avoid clot migration into anterior cerebral artery during clot extraction. Angiography determines whether there is a residual clot and whether it is suitable for aspiration now that the Sofia Plus catheter is beyond the ophthalmic artery. Alternatively, for smaller thrombi beyond the MCA bifurcation, further stent retrieval will be performed.

4) If necessary, the Sofia Plus catheter is also removed, capturing the thrombus between the stent and aspiration catheter. If angiography demonstrates a need for further thrombectomy, the process is repeated from the start.

5) Although we switched to intention to treat by aspiration-first, there had been no previous published benefit of aspiration over stent retriever. We therefore did not delay clot removal. If those steps did not work, we progressed quickly without delay to a stent retriever.

Before switching to this standardized approach, our regular approach consisted of using the same 6–8F access combination, an intermediate catheter in the distal ICA, crossing the occlusion with a microcatheter, and using a stent retriever. In general, we did not use balloon-guide catheters but rather used distal aspiration during clot retrieval through the intermediate catheter, which may have migrated into the M1 segment. There was some variation case to case of this nonstandardized approach.

Having switched to the standardized technique, we reviewed time metrics and recanalization rates to evaluate this approach. A consecutive cohort of thrombectomy procedures from our prospectively maintained stroke data base was analyzed. These were consecutive patients from 3 separate operators who have adopted this aspiration-first technique. Patients with any occlusion in the intracranial ICA and MCA M1 and M2 who were deemed suitable for thrombectomy were included, even if aspiration-first was not possible or unlikely (eg, due to M2 occlusion or tandem cervical

Table 1: Baseline characteristics

Variable/Sts	All (n = 254)	Aspiration (n = 127)	Stent Retriever (n = 127)	P Value
Age				
Mean	69.1 ± 15.6	70.4 ± 14.8	67.9 ± 16.4	.275
Median (IQR 25%–75%)	73.0 (62–80)	74.0 (63–80)	71.0 (58–79)	
NIHSS score				
Mean	15.7 ± 6.3	15.6 ± 6.7	15.7 ± 5.9	.844
Median (IQR 25%–75%)	16.0 (1–20)	15.0 (10–20)	16.0 (12–20)	
Thrombolysis (No.) (%)	132 (52.2%)	64 (50.4%)	68 (53.5%)	.662
Occlusion location (No.) (%)				
MCA, M1	176 (69%)	93 (73%)	83 (65%)	.292
MCA, M2	32 (12.6%)	12 (9%)	20 (15.7%)	
ICA, T/L	46 (18%)	22 (17%)	24 (18.8%)	
mRS 0–2 at 90 days (No.) (%)	121 (48%)	63 (50%)	58 (46%)	.53

Note:—Sts indicates statistics; T/L, carotid terminus.

ICA occlusions). The concept is to see the effect of this standardized approach in all patients. As a control, we included consecutive patients who underwent nonstandardized primary stent retrieval by the same operators during a similar time period before commencing this technique. We also analyzed specifically those cases when the aspiration technique was, in fact, the first technique used. Posterior circulation occlusions were excluded from the study. For evaluation of the success of revascularization, original TICI scores were re-evaluated by an independent neuroradiologist. If there was a disagreement from the original assessment, a third reviewer evaluated the angiograms to determine a final TICI score. We used the modified TICI score including 2c.

We compared 4 time parameters between our standardized technique and the stent retriever technique: 1) groin puncture to first angiogram, 2) groin puncture to first reperfusion, 3) time from first angiogram to first reperfusion, and 4) the duration of the procedure.

Time from groin puncture to first angiogram was used as a metric of ease/difficulty to attain a position in the ICA. This part of the procedure is unchanged from our prior technique. Time from first angiogram to first reperfusion was used to compare the speed of the techniques with achieving reperfusion, excluding any variation in difficulty in accessing the carotid artery. The overall duration of the procedure, from groin puncture to completion angiogram, was used as a metric of success of the techniques; those procedures with longer times were likely to be the more challenging cases, requiring multiple aspirations and/or multiple passes of stent retrievers. Sometimes with stent retrievers, flow is restored before pulling the stent but may be lost again, requiring further passes. This may give a false impression of the time to meaningful recanalization, which does not typically happen with aspiration.

SPSS-24 (IBM, Armonk, New York) was used for statistical analysis. Quantitative variables did not follow a standard normal distribution, as indicated by the Kolmogorov-Smirnov and Shapiro-Wilk tests. The nonparametric Mann-Whitney *U* or Kruskal-Wallis test was used to test the null hypothesis followed by the Dunn multiple comparison test to test the difference between groups. A level of significance for all analyses was $P < .05$.

RESULTS

A total of 127 consecutive patients with intracranial anterior circulation vessel occlusion underwent thrombectomy by a standardized aspiration-first technique from September 2017 to Sep-

tember 2018. This group was compared with 127 consecutive patients having undergone thrombectomies performed between April 2016 and May 2017, who were primarily treated with the stent retriever method. The baseline demographics, NIHSS score, those undergoing thrombolysis, and the TICI score are evaluated in Table 1. There was no significant difference in age, NIHSS score, and those undergoing thrombolysis between the 2 groups. In terms of vessel occlusion, there were more M2 occlusions in the stent retriever cohort; however, this was not statistically significant.

The aspiration-first technique had a median length from groin puncture to first angiogram of 6 minutes (interquartile range [IQR], 4–10 minutes) versus 5 minutes (IQR, 4–9 minutes) in the stent retriever group ($P = .234$). The aspiration-first technique had a shorter median time from the first angiogram to first reperfusion of 11 minutes (IQR, 7–20 minutes) versus 19 minutes 30 seconds (IQR, 12–32 minutes) in the stent retriever group ($P < .001$) and a shorter time from groin puncture to first reperfusion compared with the stent retriever group in the intention-to-treat group (18 versus 26 minutes, $P < .001$). The aspiration-first technique had a shorter overall procedural duration of 26 minutes (IQR, 15–41 minutes) versus 47 minutes (IQR, 32–80 minutes) in the stent retriever group ($P < .001$).

The aspiration-first technique necessitated fewer passes (mean, 2.4 versus 3.1; $P < .05$), which aided in the shorter procedural duration (Figure). Successful recanalization (TICI 2b–3) was observed in 90.9% of patients overall; 96.1% had successful recanalization (TICI 2b–3) in the aspiration-first group compared with 85.8% in the stent retriever group ($P < .005$). A higher proportion of patients had a TICI score of 2c–3 in the aspiration-first group compared with stent retriever group (78% versus 60.6%, $P < .005$). A TICI 3 result was achieved in 46% ($n = 59$) of the aspiration-first group compared with 39% ($n = 50$) in the stent retriever group ($P = .25$). There was a higher first-pass TICI 3 result in the aspiration group (25% versus 13%, $P = .01$) (Table 2).

In terms of functional outcome, 50% of those in the aspiration-first group achieved functional independence at 90 days (mRS 0–2) compared with 46% in the stent retriever–first group ($P = .53$).

In 36 patients, the aspiration catheter did not easily advance to the proximal end of the thrombus. Therefore, it was necessary to use a stent retriever first in these cases. The locations of these vessels were the MCA M1 ($n = 20$), MCA M2 ($n = 9$), MCA M3 ($n = 2$), carotid terminus ($n = 3$), and tandem cervical ICA and M2 ($n = 1$) and M1 ($n = 1$). For the remaining 91 patients, aspiration was used as the first technique. When aspiration was performed first, 18.8% of patients required rescue therapy with a stent retriever. For these patients with aspiration-first, the median time from first angiogram to reperfusion was 8 minutes, with a groin puncture to first reperfusion time of 17 minutes and overall procedural length of 22 minutes (IQR, 14–46 minutes).

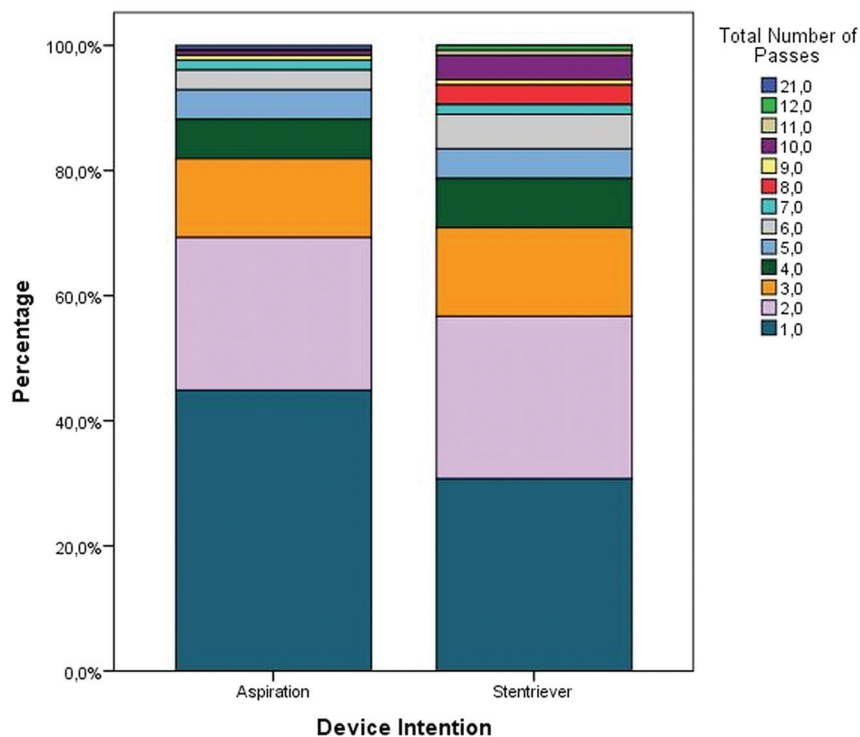


FIGURE. Type of device and the influence of total number of passes in percentages, $P < .05$

DISCUSSION

Previous randomized controlled trials showing the efficacy of thrombectomy have mainly involved the use of second-generation stent retrievers.³ However, newer technologies such as the use of aspiration devices have been developed at a greater rate than stent retriever technology through larger and more navigable catheters. The first-line aspiration technique is evolving as an established method of thrombectomy with noninferior results in terms of recanalization rates and patient outcomes compared with stent retrievers.^{7,10} Currently, there is an emphasis on reducing the time to revascularization, including the length of the procedure as well as improving the rate of recanalization, with the overall aim of improving patient outcomes.¹¹ There is continual development of novel techniques and optimization of techniques, some with very high rates of first-pass perfusion such as the Stent Retriever Assisted Vacuum-Locked Extraction (SAVE) and the Proximal Balloon Occlusion Together with Direct Thrombus Aspiration during Stent Retriever Thrombectomy (PROTECT^{Plus}) techniques.^{12,13}

There have been publications including the Contact Aspiration Versus Stent Retriever for Successful Revascularization (ASTER) randomized controlled trial (RCT), 2 meta-analyses, and the recently published COMPASS RCT evaluating the aspiration technique.^{7,10} Others report on case series of the aspiration technique but do not always define patient selection. They show varying impacts on speed and success rates with this technique. The A Direct Aspiration First Pass Technique (ADAPT) has been shown to have faster recanalization rates and reduced overall costs when used as the primary mechanism of thrombectomy compared with stent retrievers, though the results were not always statistically significant.^{4,7,14} A recently published meta-analysis has shown aspiration to have better success at

recanalization compared with stent retrievers but no benefit in terms of the number of passes or time to reperfusion.¹⁵

Our standardized approach as a technique for all anterior circulation occlusions, including tandem ICA/intracranial occlusions and occlusions beyond M1, results in shorter procedures and improved recanalization with fewer passes. We postulate that this is primarily due to the conversion to the aspiration-first technique. In our experience, it is a more streamlined and efficient process with fewer steps. Previously, we were placing an intermediate catheter distally in the ICA or even into the MCA for aspiration with a stent retriever. Changing to a method of advancing the newer, larger, and more flexible/trackable catheter as far as the clot when possible does not result in any significant delay. The clot may then be aspirated within minutes. If it does not advance to or remove the clot, a stent retriever can be easily deployed for clot retrieval without significant delay. In trial scenarios, physicians were required to try aspiration

on 3 occasions before switching to rescue therapy. In the real world, this is not required, resulting in shorter procedures. Our institution has significant experience in performing thrombectomy for acute stroke with >800 cases performed since 2010. Every procedure has a learning curve, and thrombectomy is no exception. With at least 500 cases performed prior to inclusion of any cases from the stent retriever cohort, this minimized the effect of the learning curve. Since September 2017, we have used a standardized method of setting up for attempting aspiration-first for all thrombectomy procedures. Although some improvement may be accounted for by standardization, we believe that the extensive experience before standardization would minimize this effect and that the true gain is in the use of fewer steps in most procedures.

Our median groin-to-reperfusion time in the standardized group was 18 minutes, with a mean of 26 minutes 30 seconds in comparison with 26 and 35 minutes, respectively, for the stent retriever cohort ($P < .001$) (Table 2). If we compare this to A Direct Aspiration First Pass Technique for Acute Stroke Thrombectomy (ADAPT FAST) (a multisite case series), the authors reported a mean time of 36 minutes 3 seconds.⁴ The ASTER trial was an RCT that compared revascularization rates (TICI 2b–3) as its primary outcome between the aspiration and stent retriever technique. The authors reported a median groin puncture-to-reperfusion time of 38 minutes for the aspiration group compared with 45 minutes for the stent retriever group ($P = .10$).¹⁰ The initial results from the COMPASS trial had the fastest times of any previous study, with a mean groin-to-reperfusion rate of 22 minutes for ADAPT versus 33 minutes for the stent retriever group ($P = .019$).⁷ The European Registry on the ACE Reperfusion Catheters and the Penumbra System in the Treatment of Acute

Table 2: Time variables—aspiration vs stent retriever

Variable/Sts	All (n = 254)	Aspiration (n = 127)	Stent Retriever (n = 127)	P Value
Length of procedure (min)				
Mean	47.7 ± 38.9	33.2 ± 25.1	62.2 ± 44.6	<.001
Median (IQR 25%–75%)	36.0 (22–62)	26.0 (15–41)	47.0 (32–80)	
Groin puncture to 1st angiogram (min)				
Mean	7.3 ± 5.9	7.7 ± 5.9	7.0 ± 5.8	.234
Median (IQR 25%–75%) (min)	6.0 (4–9)	6.0 (4–10)	5.0 (4–9)	
First angiogram to first 1st reperfusion (min)				
Mean	23.0 ± 25.8	18.2 ± 22.9	27.9 ± 27.6	<.001
Median (IQR 25%–75%)	15.0 (8–27)	11.0 (7–20)	19.5 (12–32)	
Groin puncture to 1st reperfusion (min)				
Mean	30.2 ± 27.1	25.6 ± 23.8	34.9 ± 29.4	<.001
Median (IQR 25%–75%)	22.0 (15–35)	18.0 (13–31)	26.0 (17–39)	
TICI (No.) (%)				
Y 2b–3	231 (90.9%)	122 (96.1%)	109 (85.8%)	<.005
2c–3	176 (69.3%)	99 (78%)	77 (60.6%)	<.005
3	109 (43%)	59 (46%)	50 (39%)	.25
First-pass 3	48 (19%)	32 (25%)	16 (13%)	.01

Note:—Y indicates TICI as standing for Thrombolysis in Cerebral Infarction Score; Sts, statistics; TICI, Thrombolysis in Cerebral Infarction Score.

Ischemic Stroke (PROMISE) observational study, which used the ADAPT technique with ACE68 and ACE64 catheters (Penumbra, Alameda, California), reported a median time to reperfusion of 31 minutes with a mean of 40 minutes.¹⁵ A meta-analysis of 17 aspiration studies versus the 5 RCTs included in the Highly Effective Reperfusion Evaluated in Multiple Endovascular Stroke (HERMES) meta-analysis recorded a trend toward a shorter procedural time with the aspiration group (44 minutes 42 seconds versus 61 minutes 28 seconds, $P = .088$).¹⁶

Observing groin puncture-to-reperfusion times is not the full story, however. For our described aspiration-first technique, the times from groin puncture to first angiogram are comparable with the conventional technique, without a statistically significant difference. This part of the procedure has not changed and has a similar patient cohort in terms of difficulty/ease of vascular access to the ICA. The main benefit of our technique comes after this stage, however, when the time from the first angiogram to the first restoration of flow is significantly shorter at 11 minutes (IQR, 7–20 minutes) versus 19 minutes 30 seconds (IQR, 12–32 minutes) in the stent retriever group, ($P < .001$) (8 minutes when aspiration is actually used first). Our overall procedure length is 26 minutes (22 minutes [IQR, 14–46 minutes] when aspiration is actually the first device used). These specific figures are not quoted in other studies; however, they highlight the speed of the aspiration technique once access is achieved, resulting in a much shorter procedural length.

In terms of reperfusion rates, 96% of the patients in the standardized aspiration-first group had a TICI of 2b–3 compared with 85.8% in the stent retriever cohort ($P < .005$) (Table 2). The ASTER and COMPASS trials reported rates of 85.4% and 83.2%, respectively, for the ADAPT technique.^{7,10} These trials did not show improved recanalization rates for ADAPT. If we examine the TICI 2c–3 rates alone, we report a rate of 78% for the aspiration approach versus 61% in the stent retriever cohort ($P < .005$). The ASTER trial separately evaluated TICI 2c–3 with rates of 56.3% and 56.6% for aspiration and stent retriever, respectively.¹⁰

The PROMISE study reported successful reperfusion rates (TICI 2b–3) of 93.1%.¹⁵ The ADAPT FAST study reported overall revascularization rates (TICI 2b–3) of 95%, and when aspiration was used alone, it was successful in achieving revascularization 78% of the time compared with our rate of 94.5% for this group.⁴ The meta-analysis of ADAPT versus the HERMES meta-analysis where stent retrievers were used by Phan et al¹⁶ showed significantly higher revascularization rates in the ADAPT group compared with stent retriever group (89.6% versus 71.7%, $P < .001$), though most groups appear to show improved recanalization rates now compared with HERMES.

In our study, when aspiration was performed first, 18.8% of cases required rescue therapy with a stent retriever, an outcome comparable with or lower than other reported studies. This may be due to operator-related factors and slight differences in occlusion location. In the ASTER trial, rescue treatment was required in 32.8% of patients in the aspiration group, 20.9% in the PROMISE study and 21% in COMPASS.^{7,10,15} The ASTER and PROMISE studies included 48 (27.6%) and 37 (18.1%) M2 branch occlusions, respectively, compared with our rate of 7.8% in the aspiration group and 14% in the stent retriever group.^{10,15} We believe that our higher rates of recanalization and lower use of rescue therapy following aspiration are likely due to using a larger bore catheter with excellent trackability. Larger bore catheters enable generation of greater aspiration pressure and presumably accommodate larger clots.

First restoration of flow does not necessarily equate with removal of the entire clot and further passes may be required. This is particularly the case with stent retrievers when you can get flow restoration without even removing the clot. Our aspiration-first group required fewer passes, and 45% ($n = 57$) needed only a single pass when aspiration was used first, compared with 35% ($n = 39$) in the stent retriever group, resulting in an overall shorter procedural time. The ASTER RCT reported no difference in the number of attempts between the 2 groups, with a median number of 2 passes.¹⁰ The PROMISE trial reported a median number of 2 passes before using adjunctive therapy.¹⁵ The authors of the ADAPT FAST study stated that they often only needed a single pass to achieve successful reperfusion; however, they did not quote exact figures.⁴

In terms of good functional outcome, our rates are comparable with those in both the ASTER and COMPASS RCT, yielding rates of 45.5% and 52%, respectively, for the aspiration-first technique group, while ADAPT FAST had slightly lower rates of 40% in this group.^{4,7,10} The PROMISE study had the highest rates of good functional outcome, with a rate of 60% compared with our rate of 50%; however, their inclusion criteria were limited to patients with onset of symptoms within 6 hours.¹⁵

A potential advantage of aspiration over stent retrievers is the

potential for fewer procedure-related complications resulting from direct trauma to the vessels caused by the stent retrievers. It is not fully understood where crossing a clot (MCA for example) results in any injury to the vessel wall, intima or media. It has been shown that using a microwire to cross a clot can result in vessel injury compared with using a microcatheter alone.¹⁷ Focal acceleration of blood flow velocities after mechanical thrombectomy is suggestive of residual stenosis or vasospasm, and this may be a sign of endothelial layer disruption/intimal injury.¹⁸ Intracranial arterial wall thickening and enhancement have been demonstrated postthrombectomy, indicating an arteritis.¹⁹ A study comparing vascular damage in ADAPT versus stent retrievers in animal models showed almost complete loss of the endothelium when stent retrievers were used. As we have described, our study showed fewer passes compared with stent retrievers. Furthermore, fewer passes will also lead to less disruption of clot, potentially leading to less risk of resulting emboli to a new territory (ENT).²⁰ The ADAPT FAST study reported no cases of ENT, while PROMISE reported a rate of 1.5%.^{4,15} Use of the ADAPT technique has been reported to increase the risk of ENT.²⁰ However, with newer, larger catheters such as the Sofia Plus, there is likely to be a higher rate of clot ingestion as opposed to pulling the clot through the circulation, preventing ENT. A recent meta-analysis published in September 2018 evaluated 9 studies comparing the efficacy and safety of the direct aspiration technique versus stent retrievers. This study showed fewer cases of symptomatic intracranial hemorrhage (4.8% versus 8.35%) and embolization to a new territory (5.1% versus 9.7%) with direct aspiration.²¹ Newer aspiration catheters, which are more flexible and atraumatic compared with stent retrievers, will arguably lead to less procedure-related complications.

The strengths of our study lie in the standardized approach used for consecutive patients, resulting in faster and better outcomes with no disadvantages for cases that need to be switched to stent retrievers, because this can be performed without a change in the setup. Furthermore, the consecutive nature of case selection and lack of difference between the groups, including similar groin puncture to first angiogram times, confirms the absence of selection bias or cherry-picking. While previous studies have shown comparable times and recanalization rates, we have been able to demonstrate significantly faster and better recanalization rates and fewer passes compared with stent retrievers.

A weakness in our study is that it is a single-center study that did not use a core laboratory in the assessment of TICI scores. However, final TICI scores required agreement by 2 independent neuroradiologists. Although the use of balloon-guide catheters is recommended by many, we have not developed this as a routine due to a preference for having larger bore intermediate catheters for distal aspiration in conjunction with a stent retriever. Nevertheless, our recanalization rates with our stent retriever cohort are comparable with those in other published series. We did not use the recently available Wedge device (MicroVention) designed to get the aspiration/Sofia catheter past the ophthalmic artery, which may help aspiration-first work in a higher percentage of patients. The effectiveness of this device is yet to be established. Furthermore, we did not use a smaller aspiration catheter that could have

reached more distal branches. It is likely that the rate of successful navigation of the aspiration catheter to the thrombus will improve with better technology and range of catheters.

CONCLUSIONS

In a procedure in which “time is brain,” any opportunity to improve times and success should be taken. This approach uses a standardized technique already possibly familiar to many neurovascular interventionalists and is potentially widely adaptable. By using this technique, we have demonstrated faster and better recanalization times with an overall reduced procedure length.

ACKNOWLEDGMENTS

The authors wish to express their gratitude to Dr Sean Fitzgerald for his contribution to this article.

Disclosures: Karen M. Doyle—RELATED: Grant: Science Foundation Ireland and Cerenovus.* John Thornton—UNRELATED: Board Membership: Neuravi, Comments: Scientific Advisory Board. *Money paid to the institution.

REFERENCES

1. Saver JL. **Time is brain—quantified.** *Stroke* 2005;37:263–66 Medline
2. Campbell BC, Donnan GA, Lees KR, et al. **Endovascular thrombectomy: the new standard of care for large vessel ischaemic stroke.** *Lancet Neurol* 2015;14:846–54 CrossRef Medline
3. Goyal M, Menon BK, van Zwam WH, et al; HERMES collaborators. **Endovascular thrombectomy after large-vessel ischaemic stroke: a meta-analysis of individual patient data from five randomised trials.** *Lancet* 2016;387:1723–31 CrossRef Medline
4. Turk AS, Frei D, Fiorella D, et al. **ADAPT FAST study: a direct aspiration first pass technique for acute stroke thrombectomy.** *J Neurointerv Surg* 2014;6:260–64 CrossRef Medline
5. Jankowitz B, Aghaebrahim A, Zirra A, et al. **Manual aspiration thrombectomy: adjunctive endovascular recanalisation technique in acute stroke interventions.** *Stroke* 2012;43:1408–11 CrossRef Medline
6. Massari F, Henninger N, Lozano JD, et al. **ARTS (Aspiration-Retriever Technique for Stroke): initial clinical experience.** *Interv Neuroradiol* 2016;22:325–32 CrossRef Medline
7. Turk AS 3rd, Siddiqui A, Fifi JT, et al. **Aspiration thrombectomy versus stent retriever thrombectomy as first-line approach for large vessel occlusion (COMPASS): a multicentre, randomised, open label, blinded outcome, non-inferiority trial.** *Lancet* 2019;393:998–1008 CrossRef Medline
8. Holodinsky JK, Patel AB, Thornton J, et al. **Drip and ship versus direct to endovascular thrombectomy: the impact of treatment times on transport decision-making.** *Eur Stroke J* 2018;3:126–35 CrossRef Medline
9. Singh J, Wolfe SQ, Janjua RM, et al. **Anchor technique: use of stent retrievers as an anchor to advance thrombectomy catheters in internal carotid artery occlusions.** *Interv Neuroradiol* 2015;21:707–09 CrossRef Medline
10. Lapergue B, Blanc R, Gory B, et al; ER Trial Investigators. **Effect of endovascular contact aspiration vs stent retriever on revascularization in patients with acute ischemic stroke and large vessel occlusion: the ASTER randomized clinical trial.** *JAMA* 2017;318:443–52 CrossRef Medline
11. Goyal M, Demchuk AM, Menon BK, et al; ESCAPE Trial Investigators. **Randomized assessment of rapid endovascular treatment of ischemic stroke.** *N Engl J Med* 2015;372:1019–30 CrossRef Medline
12. Maus V, Behme D, Kabbasch C, et al. **Maximizing first-pass complete reperfusion with SAVE.** *Clin Neuroradiol* 2018;28:327–38 CrossRef Medline
13. Maegerlein C, Berndt MT, Monch S, et al. **Development of combined**

- techniques using stent retrievers, aspiration catheters and BGC: the PROTECT^{PLUS} technique. 2018 Nov 9. [Epub ahead of print] CrossRef Medline
14. Turk AS, Turner R, Spiotta A, et al. **Comparison of endovascular treatment approaches for acute ischemic stroke: cost-effectiveness, technical success, and clinical outcomes.** *J Neurointerv Surg* 2015;7:666–70 CrossRef Medline
 15. Schramm P, Navia P, Papa R, et al. **ADAPT technique with ACE68 and ACE64 reperfusion catheters in ischemic stroke treatment: results from the PROMISE study.** *J Neurointerv Surg* 2019;11:226–31 CrossRef Medline
 16. Phan K, Dmytriw AA, Teng I, et al. **Direct aspiration first pass technique vs standard endovascular therapy for acute stroke: a systematic review and meta-analysis.** *Neurosurgery* 2018;83:19–28 CrossRef Medline
 17. Keulers A, Nikoubashman O, Mpotsaris A, et al. **Preventing vessel perforations in endovascular thrombectomy: feasibility and safety of passing the clot with a microcatheter without microwire: the wireless microcatheter technique.** *J Neurointerv Surg* 2018 Dec 7. [Epub ahead of print]. CrossRef Medline
 18. Perren F, Kargiotis O, Pignat JM, et al. **Hemodynamic changes may indicate vessel wall injury after stent retrieval thrombectomy for acute stroke.** *J Neuroimaging* 2018;28:412–15 CrossRef Medline
 19. Power S, Matouk C, Casaubon LK, et al. **Vessel wall magnetic resonance imaging in acute ischemic stroke: effects of embolism and mechanical thrombectomy on the arterial wall.** *Stroke* 2014;45:2330–34 CrossRef Medline
 20. Chueh J, Puri AS, Wakhloo AK, et al. **Risk of distal embolization with stent retriever thrombectomy and ADAPT.** *J Neurointerv Surg* 2016;8:197–202 CrossRef Medline
 21. Qin C, Shang K, Xu SB, et al. **Efficacy and safety of direct aspiration versus stent retriever for recanalization in acute cerebral infarction: A PRISMA-compliant systematic review and meta-analysis.** *Medicine (Baltimore)* 2018;97:e12770 CrossRef Medline